



PATIENT

Jelly Kaufman

SPECIES

Canine

BREED

Norwich Terrier

SEX

Female Spayed

AGE

8 years

WEIGHT

17.2lbs

INTERPRETED BY

Maggie Machen
Lamy, DVM
DACVIM (Cardiology)

IMAGING PERFORMED BY

Pamela Harrigan,
RDCS

HOSPITAL NAME

New England Animal
Medical Center

REFERRING VET

Dr. Doyon

PRESENTING CLINICAL SIGNS

History: Referred yesterday in CHF. Known pre-existing heart disease; never been in failure. Referring hospital records not available. Per owner, Jelly received Pimobendan, Enalapril, Spironolactone and dasequin. On exam, grade IV/VI systolic murmur; dyspneic, bilateral crackles. In hospital on Lasix, CRI, Pimobendan (2.5 mg TID), O2 dependent.

ELECTROCARDIOGRAPHIC FINDINGS *Note: Single lead ECGs are evaluated as a rhythm strip. Morphology/MEA cannot be definitively commented on.

A single lead ECG is available; 25mm/s, 20mm/mV. The average heart rate is 100bpm (range 62-115bpm). The rhythm is sinus in origin, with a p for every QRS complex and vice versa. P and QRS morphologies are positive. Isolated VPCs throughout; 5 in a 90 second recording. Singles only. No supraventricular premature beats, pauses or other dysrhythmias observed.
ECG diagnosis: Respiratory sinus arrhythmia with isolated VPCs.

ECHOCARDIOGRAM FINDINGS

2D, m-mode, color flow and Doppler imaging is available.
Left ventricle: Significant LV dilation with hyperdynamic myocardial function.
Left atrium: The left atrium is markedly dilated.
Mitral valve: Mild thickening of mitral valve leaflets with mild prolapse into the left atrial lumen. Severe eccentric mitral regurgitation with a normal velocity.
Aortic valve/Aorta: The aortic valve is normal in morphology and mobility. Normal aortic outflow velocity; laminar flow. Trace aortic insufficiency.
Right ventricle: Mild RV dilation.
Right atrium: Mild right atrial dilation.
Tricuspid valve: The tricuspid valve appears thickened, with mild tricuspid regurgitation. Normal velocity.
Pulmonic valve/Pulmonary artery: The pulmonic valve is normal in morphology and mobility. The MPA appears mildly dilated. Normal pulmonic outflow velocities with laminar flow. No PI.
Pericardium/other: No pericardial or pleural effusion noted. No obvious cardiac masses.

2-Dimensional Measurements

Ao diam (cm)	1.3
LA diam (cm)	4.0
LA:Ao (Swe)	3.0
IVS thickness (cm)	0.7
LVID diastole (cm)	3.7
PW thickness (cm)	0.7
LVID systole (cm)	1.7
FS (%)	55

Doppler Measurements

PV Vmax (m/s)	0.75
AoV Vmax (m/s)	1.7
MR Vmax (m/s)	4.9
TR Vmax (m/s)	2.9
TR PG (mmHg)	34

INTERPRETATION OF THE FINDINGS

The cause of the murmur is chronic degenerative valve disease causing severe mitral and mild tricuspid regurgitation. Marked left atrial enlargement indicates the risk for spontaneous congestive heart failure is elevated. A small aortic leak is noted, and a baseline blood pressure is recommended. No additional issues are identified.

INVOICE

21910

DATE

11/8/21

In light of the clinical signs and severity of disease on echocardiogram, the most likely diagnosis is congestive heart failure and continued medications are warranted lifelong as



PATIENT

Jelly Kaufman

SPECIES

Canine

BREED

Norwich Terrier

SEX

Female Spayed

AGE

8 years

WEIGHT

17.2lbs

INTERPRETED BY

Maggie Machen
 Lamy, DVM
 DACVIM (Cardiology)

IMAGING PERFORMED BY

Pamela Harrigan,
 RDCS

HOSPITAL NAME

New England Animal
 Medical Center

REFERRING VET

Dr. Doyon

INVOICE

21910

DATE

11/8/21

below. The ECG does show a relatively low resting heart rate which is unusual for a patient with simple CHF (ie should be highly sympathetically driven). Strongly recommend chest radiographs if not performed to ensure a primary respiratory component is not at play. If respiratory disease is ruled out as a contributing factor, this patient may have concurrent sinus node dysfunction that will limit outcome. Monitoring of the heart rate in hospital is recommended going forward. Additionally, the ECG shows isolated VPCs which is less surprising given the degree of disease and a decompensated patient. No treatment is indicated at this time; however, follow up is advised.

The average survival time of canine patients with active pulmonary edema is 8-9 months on medications, however they generally are able to maintain a good quality of life for that period. Patient will always be at risk for recurrent CHF, development of arrhythmias/LA tear, syncope and/or sudden death in the future.

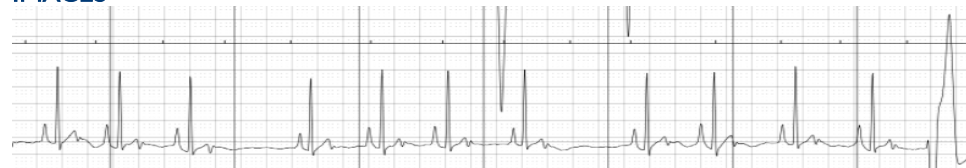
RECOMMENDATIONS

- If not performed, highly recommend baseline chest radiographs with a Radiologist review.
- If the patient is stable for oral medications in hospital, continue Pimobendan 0.3mg/kg PO q12h and Spironolactone 1-2mg/kg PO q12h orally.
- Continue injectable Lasix therapy, assuming CHF is confirmed until the patient is stable on room air. Discharge on 1-2mg/kg PO q12h.
- Cough suppression to improve QOL can also be considered (hydrocodone, 0.2-0.4mg/kg up to q4-6h PRN) for any residual mechanical cough in the face of normal sleeping respiratory rates.
- Monitor for development of a cough, labored breathing, exercise intolerance or collapse episodes.
- Monitoring of sleeping respiratory rates will be paramount to screen for congestive heart failure at home.
- Elective anesthesia is not advised.
- Omega fatty acid supplementation and mild salt restriction may be of some long-term benefit.

PLAN

- Monitor renal values, ECG and BP in 1-2 weeks, then every 3-4 months lifelong. If doing well and BP >130mmHg, institute ACEI 0.5mg/kg PO q12h.
- Recommend conservative monitoring with a recheck echocardiogram in 6 months, sooner if any development of clinical signs.

IMAGES





PATIENT

Jelly Kaufman

SPECIES

Canine

BREED

Norwich Terrier

SEX

Female Spayed

AGE

8 years

WEIGHT

17.2lbs

INTERPRETED BY

Maggie Machen
 Lamy, DVM
 DACVIM (Cardiology)

IMAGING PERFORMED BY

Pamela Harrigan,
 RDCS

HOSPITAL NAME

New England Animal
 Medical Center

REFERRING VET

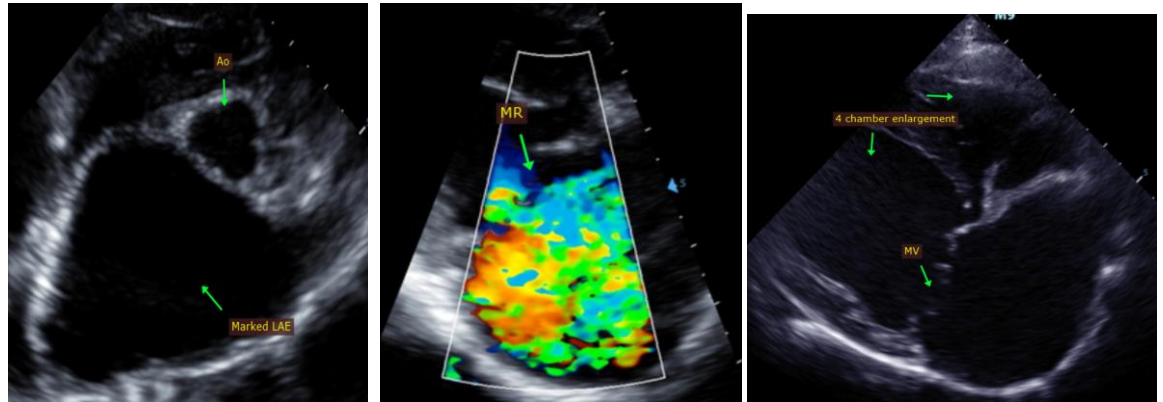
Dr. Doyon

INVOICE

21910

DATE

11/8/21



The information and recommendations provided are based on the images presented by the referring veterinarian. No evaluation can be communicated regarding pathology that was not visible in the image/video clips provided.

Thank you for this referral. This report was generated using transcription software, and minor dictation errors may be present. If the clinical or image interpretation does not parallel your findings or if I can be of any further assistance, please contact me.

Maggie Machen Lamy, DVM
 Diplomate of the American College of Veterinary Internal Medicine (Cardiology)
 info@sonopath.com